

Absence of the posterior arch of the atlas

JORGE IGNACIO MAGAÑA-REYES, LUIS GERARDO DOMÍNGUEZ-CARRILLO • LEÓN (MÉXICO)

DOI: <https://doi.org/10.36104/amc.2022.2360>

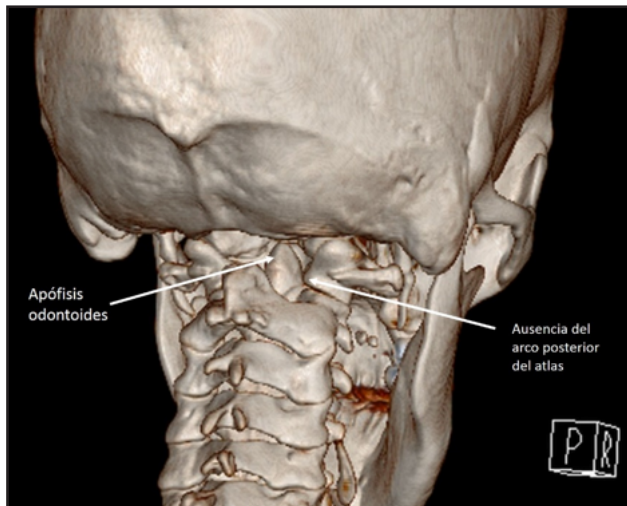


Figure 1. Computed tomography image with 3D reconstruction of the posterior cervical spine, showing total absence of the posterior arch of the atlas, with a direct view of the odontoid process.

Congenital defects of the posterior arch of the atlas have an estimated incidence of 0.7 to 3% (1). Most patients are asymptomatic and incidentally diagnosed on cervical spine x-rays, and these defects may be mistaken for fractures or proximal dislocations of the cervical spine (2). (Figure 1). Embryologically, there are three ossification centers in the atlas during the seventh week of gestation: the central anterior one produces the anterior tubercle, and the two central lateral ones form the lateral masses and posterior arch which includes the posterior tubercle. Two percent of the population has a fourth ossification center which forms the posterior tubercle; fusion occurs sometime between 3 and 10 years of age (3). Currarino's classification (4) mentions five types of anomalies (Figure 2), with type A occurring in 95% of cases; the presented case is categorized as type E.

References

1. Sabuncuoğlu H, Ozdoğan S, Karadag D, Kaynak ET. Congenital hypoplasia of the posterior arch of the atlas: case report and extensive review of the literature. *Turk Neurosurg.* 2011; **21**: 97-103.
2. Ouyang ZY, Qiu MJ, Zhao Z, Wu XB, Tong LS. Congenital anomaly of the posterior arch of the atlas: a rare risk factor for posterior circulation stroke. *J Neurointerv Surg.* 2017; **9** (7): e27. doi: 10.1136/neurintsurg-2016-012731.
3. Junewick JJ, Chin MS, Meesa IR, Ghorri S, Boynton SJ, Luttenton CR. Ossification patterns of the atlas vertebra. *AJR Am J Roentgenol.* 2011; **197**: 1229-1234.
4. Currarino G, Rollins N, Diehl JT. Congenital defects of the posterior arch of the atlas: a report of seven cases including an affected mother and son. *AJNR Am J Neuroradiol.* 1994; **15**: 249-254.

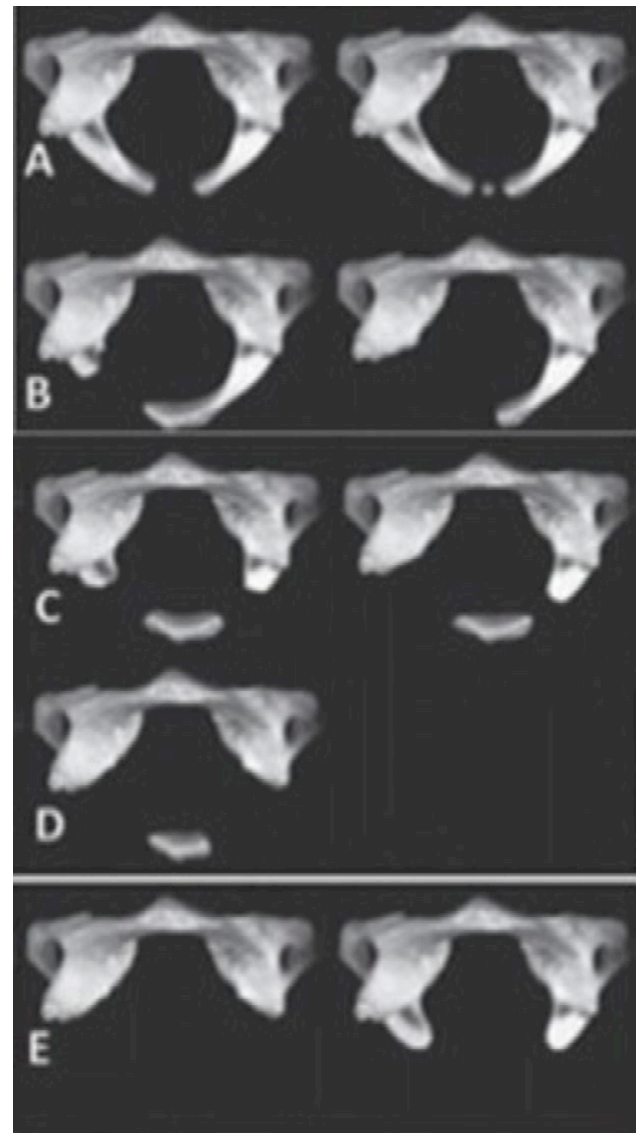


Figure 2. Currarino's classification (4) showing the different types of congenital anomalies of the posterior arch of the atlas. Type A: lack of midline fusion of the posterior arches; B: unilateral cleft due to an absent hemiarch; C: absence of both hemiarches; D: total absence of the posterior arch with a persistent posterior tubercle; E: total absence of the posterior arch and absence of the posterior tubercle.

Dr. Jorge Ignacio Magaña-Reyes: Especialista en Radiología e Imagenología. Gestalt Imagen, León, Guanajuato; Dr. Luis Gerardo Domínguez-Carrillo: Especialista en Medicina de Rehabilitación. Catedrático Facultad de Medicina de León, Universidad de Guanajuato. León (México).

Correspondencia: Dr. Luis Gerardo Domínguez Carrillo. León (México).

E-Mail: lgdominguez@hotmail.com Received: 7/X/2021 Accepted: 3/XI/2021