

Extrapulmonary tuberculosis as acute tuberculous appendicitis

JAIRO JAIRD VERGARA-CORENA, LUIS ALFREDO BLANCO-CASTIBLANCO,
GILBERTO RAFAEL MANGONES-ORTEGA, KEIMER JOSÉ MEJÍA-FLÓREZ • SINCELEJO (COLOMBIA)

DOI: <https://doi.org/10.36104/amc.2021.1896>

Abstract

Introduction: appendicitis is the most frequent abdominal surgical emergency, but tuberculosis as the etiological agent makes this case special, due to its very low frequency of 0.1 to 0.6%. Its incidental finding guided us to seek other involved organs and begin specific treatment. This is the first case report in our region.

Case report: a 33-year-old woman with a history of primary adrenal insufficiency being treated with fludrocortisone consulted due to right lower quadrant abdominal pain, fever and emesis, associated with leukocytosis with a left shift and a pathological urinalysis. A urinary tract infection was suspected, and antibiotic therapy was begun with no improvement. She was therefore seen by general surgery, who suspected acute abdomen arising from appendicitis. She underwent surgery with a subsequent histopathological study which suggested caseifying granulomatous inflammation compatible with tuberculosis, with ensuing proof of acid-fast bacilli using Ziehl Neelsen staining.

Conclusion: Extrapulmonary tuberculosis has diverse clinical presentations. Therefore, when faced with atypical manifestations of this disease we should maintain a level of suspicion. Acute tuberculous appendicitis generally presents in the context of an immunosuppressed patient, and its etiological diagnosis is carried out after surgery. Therefore, it is essential to be vigilant and review the biopsy result and stains, which will allow specific treatments to be carried out. (*Acta Med Colomb* 2021; 46. DOI: <https://doi.org/10.36104/amc.2021.1896>).

Key words: *appendicitis, intestinal tuberculosis, acute abdomen, extrapulmonary tuberculosis.*

Dr. Jairo Jairo Vergara-Corena: Médico Internista Universidad de Sucre, Clínica Salud Social; Dr. Luis Alfredo Blanco-Castiblanco: Médico Urgencias; Dr. Gilberto Rafael Mangones-Ortega: Cirugía General y Laparoscópica; Dr. Keimer José Mejía-Flórez: Médico Urgencias. **Clínica Salud Social.** Sincelejo (Colombia).
Correspondencia: Dr. Jairo Jairo Vergara-Corena. Sincelejo (Colombia).
E-mail: jairovergara2011@gmail.com
Received: 27/VI/2020 Accepted: 22/VII/2020

Introduction

Appendicitis is the most common abdominal surgical emergency. It is triggered by obstruction of the appendix due to lymphoid hyperplasia, parasitosis, foreign bodies, or neoplasms, among others. A tuberculous origin is estimated to account for 0.1 to 0.6% of cases (1, 2), making it an uncommon, difficult to diagnose condition, which makes this case's clinical presentation very interesting.

Tuberculosis (TB) is a contagious disease caused by Koch's bacillus, a strictly aerobic, acid-alcohol fast bacterium able to cause fibrotic and inflammatory changes, predominantly in the lungs. Extrapulmonary forms make up 10-30% of the cases, with digestive tract TB being responsible for 1% of these forms (2, 3).

Case report

A 33-year-old woman with a history of primary adrenal insufficiency, being treated with fludrocortisone, consulted due to right flank and iliac fossa pain associated with spiking fevers and episodes of emesis. She was admitted in pain, with generalized abdominal pain on palpation, although without signs of peritoneal irritation. A complete blood count was ordered showing leukocytosis with neutrophil

predominance, and a urinalysis revealed leukocyturia and bacteriuria. She was thought to have a possible urinary tract infection and empirical antibiotic treatment was ordered with a third-generation cephalosporin, with a urine culture taken prior to treatment. A complete abdominal ultrasound was requested, which was normal. She showed no clinical improvement after 24 hours of treatment, and therefore was seen by general surgery, who diagnosed probable acute appendicitis. An appendectomy was performed using the Rocky Davis approach, identifying a fibrinopurulent cecal appendix (Figure 1) with localized peritonitis. A subsequent histopathological exam reported granulomatous caseifying chronic inflammation compatible with TB infection. A Ziel-Neelsen stain was ordered, which was positive for AARB (Figures 2, 3).

After microbiological confirmation, the initial phase (two months) of antituberculous treatment was begun with isoniazid, rifampicin, pyrazinamide and ethambutol (HRZE), with its ensuing follow up by the public health department. Imaging studies with contrast were also ordered, which, despite a lack of respiratory symptoms, showed pulmonary parenchymal changes with a miliary pattern and peri-omental thickening related to the histological changes described.

Discussion

Tuberculosis is a public health problem which has been increasing due to poor sanitation and hygiene conditions, migration, immunodeficiencies and the use of immunosuppressants (4). In Colombia, in 2011, there was an estimated incidence of 24.5/100,000 inhabitants, with a 14-20% increase in extrapulmonary disease (5).

In the retrospective clinical integration of this case, it is important to highlight the preexisting health conditions; the use of immunosuppressants and their relationship with the main clinical sign which was abdominal pain; and the differential diagnoses of urinary infection vs. urinary signs of acute appendicitis, with existing descriptions of pathological urinalyses showing leukocyturia and hematuria and symptoms of urinary irritation in acute appendicitis (6), which may lead, unsurprisingly, to syndromic diagnostic errors on patient admission. This is a lesson from this case; it is very hard to think of appendicular TB as an etiology of appendicitis, first of all because it is not the most common extrapulmonary location of TB, and abdominal TB is less frequent than other extrapulmonary locations such as the lymph system, genitourinary system, bone and meninges (7). In 75% of cases, abdominal involvement is located in areas with more lymphoid tissue and a large absorption capacity, such as the peritoneal cavity, ileocecal and jejunum-ileal region, as well as its superior mesenteric and paraaortic drainage nodes (8).

The diagnostic methods we used were correct and the literature supports us. *Mycobacterium tuberculosis* must be isolated and microbiologically identified. The methods with the greatest sensitivity and specificity are culture, polymerase chain reaction and staining (ZN), with the latter being the most frequently used due to its low cost and prompt results for beginning an antituberculous treatment regimen (9).

This case is very important primarily because the clinical picture was atypical for the final etiological diagnosis, where initial suspicion of the disease was unlikely. Postoperative follow up is essential along with a review of the diagnostic methods, in this case biopsy and special stains. This is the first case report in our region, in the department of Sucre, contributing epidemiological evidence to extrapulmonary tuberculosis cases in Colombia and the Caribbean Region.

With regard to treatment, six months of first-line tuberculostatics (HRZE) are ordered in most cases, distributed in an initial two-month phase and a subsequent four-month consolidation phase (10, 11).

Acknowledgements

We would like to thank the Clínica Salud Social and the patient for helping us develop this type of scientific evidence which can contribute to research in our local setting.

References

1. Sharath Chandra BJ, Girish TU, Thrishuli PB, Vinay HG. Primary Tuberculosis of the Appendix: A Rare Cause of a Common Disease. *J Surg Tech Case Rep.* 2013;5(1):32-34.

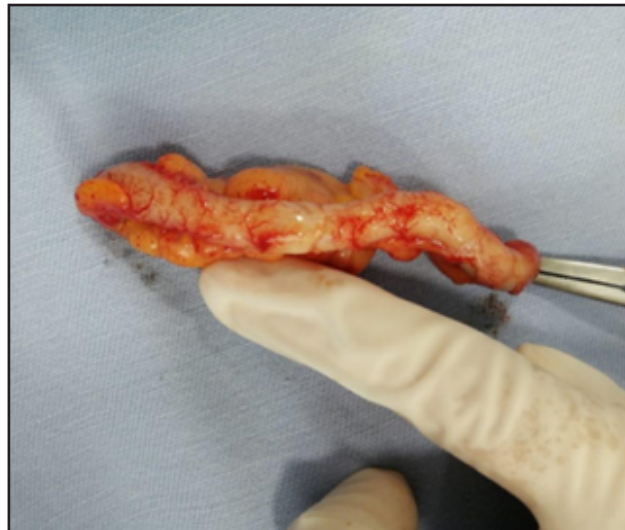


Figure 1. Cecal fibrinopurulent appendix measuring 7*1.5 cm.

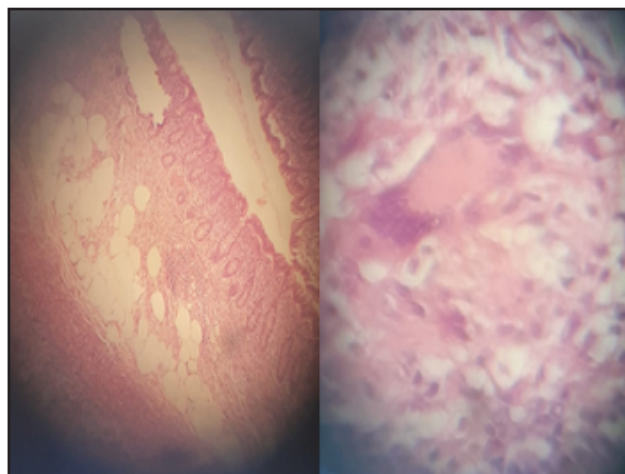


Figure 2. Cecal appendix; chronic inflammatory process.

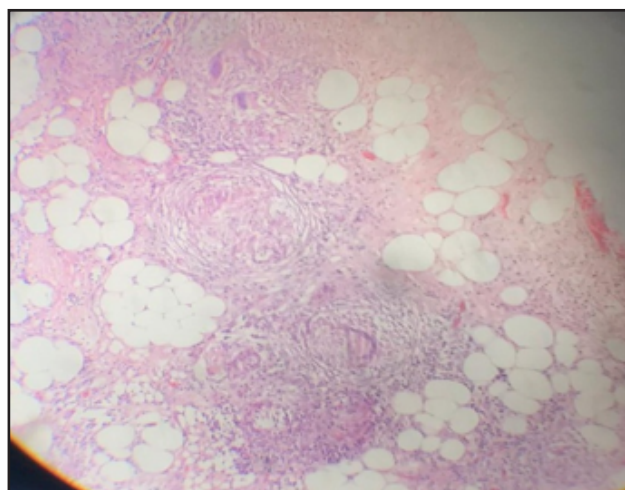


Figure 3. Omentum; adipose tissue with granulomatous cells, with Langhans multinucleated giant cells and caseous necrosis surrounded by lymphocytes..

2. **Santana-Ortiz R, Ortiz-Mojica HG, Rodríguez-Rodríguez IC, Baltazar-Guerrero JE, Pérez-Rulfo ID, Duque-Zepeda F, Orozco-Pérez J, Yanowsky-Reyes G.** Apendicitis tuberculosa. *Rev Med MD* 2018; 9.10 (3)
3. **Montiel-Jarquín AJ, Alvarado-Ortega I, Romero-Figueroa MS, Rodríguez-Pérez F, Rodríguez-Lima F, Loria-Castellanos J.** Abdomen agudo ocasionado por apendicitis aguda de probable origen tuberculoso. Informe de un caso. *Iatreia*. 2017 Jul-Sept;30(3): 321-325. DOI 10.17533/udea.iatreia.v30n3a07
4. **Guirat A, Koubaa M, Mzali R, Abid B, Ellouz S, Affes, et al.** Peritoneal tuberculosis. *Clin Res Hepatol Gastroenterol.*, 35 (2011), pp. 60-69
5. **Solier Insuasty J, Bolivar A, Calvo LS, Roberto SL.** Tuberculosis peritoneal simulando cáncer de ovario. Peritoneal tuberculosis simulating ovarian cancer. *Acta Médica Colomb.*, 2008 (2014), pp. 383-387
6. **Tundidor A, Amado J, Montes J.** manifestaciones urinarias de la apendicitis aguda. *Arch. Esp. Urol.* 2005; 58: 207-212.
7. **Marshall JB.** Tuberculosis of the gastrointestinal tract and peritoneum. *Am J Gastroenterol* 1993;88:899-999
8. **Rodríguez E, Beltrán E, Ribas J, Torres M.** apendicitis aguda como inicio de una tuberculosis generalizada. *Gastroenterol Hepatol* 2004;27(1):43-4
9. **Gan HT, Chen YQ, Ouayang Q, bu H, Yang XY.** Differentiation between intestinal tuberculosis and Chron's disease in endoscopic biopsy specimens by polymerase chain reaction. *Am J Gastroenterol* 2002; 97: 1446-1451
10. **Saigal S, Agarwal SR, Nandeesh HP, Sarin SK.** Safety of an ofloxacin-based antitubercular regimen for the treatment of tuberculosis in patients with underlying chronic liver disease: A preliminary report. *J Gastroenterol Hepatol.*, 16 (2001), pp. 1028-1032
11. **Udwadia ZF, Sen T.** Pleural tuberculosis: an update. *Curr Opin Pulm Med.* 2010 Jul;16(4):399-406

